

Massive Ovarian Oedema in a 23-year-old Patient: A Case Report

SUPRIYA MEHROTRA¹, BANDANA MEHROTRA², SANJAY MEHROTRA³, ASHOK KUMAR KAPOOR⁴, HARI SHYAM⁵

ABSTRACT

Massive Ovarian Oedema (MOE) is a rare gynaecological disorder that has been rarely reported in our country. Approximately six cases have been reported previously in India. The lesion may either present as a primary disease or develop secondarily, subsequent to an ovarian lesion or pregnancy. Moreover, the primary lesion may induce strangulation of blood vessels and lymphatics, resulting in ischaemia. If abdominal pain persists, the patient may require laparoscopic salpingo-oophorectomy. A 23-year-old female in the reproductive age group developed pain in the lower pelvic region. Upon examination, she exhibited unilateral enlargement of the right ovary. On palpation, an abdominal/pelvic mass was noted. The patient underwent surgery. The ovary was sectioned, and several slices of approximately 1 cm thickness were prepared. A significant amount of water-like serous fluid emerged from the cut surface. A few areas with a gelatinous appearance were also observed. Other findings from the current lesion included necrosis and haemorrhage, along with signs of fibrosis. Extensive fibrosis may lead to strangulation. Most of the cysts contained watery serous fluid. Persistent strangulation of the ovarian pedicle might have resulted in massive oedema. The presence of adult worms of *Enterobius vermicularis* in the appendix of the patient with MOE might have an aetiological role.

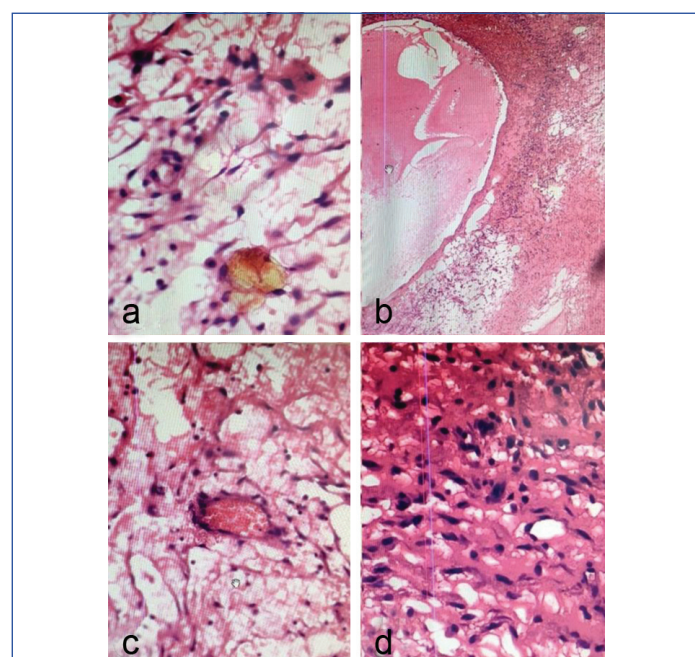
Keywords: Cysts, Fibrosis, Torsion ischaemia

CASE REPORT

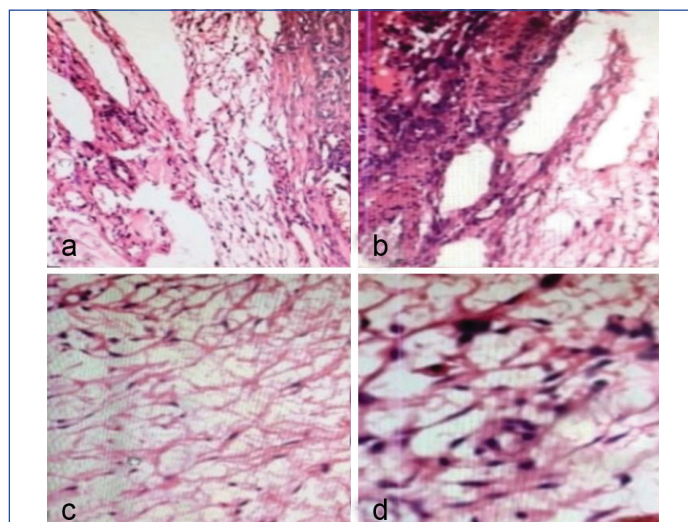
A 23-year-old female patient complained of pain in the lower abdomen along with a large palpable pelvic tumour. She had noticed the swelling for approximately one year. She underwent surgery, during which the right ovary was excised. The specimen consisted of a large, ovoid ovary, measuring 9x6x4 cm. The cut surface of the right ovary exhibited a soft, boggy appearance. Several cysts were observed at the periphery, which were filled with copious watery fluid.

Microscopically, the section displayed marked stromal oedema with thin-walled blood vessels. Numerous microcysts were identified [Table/Fig-1a]. A macrocyst was also observed [Table/Fig-1b]. [Table/Fig-1c] shows microcysts alongside a capillary. Fibrocollagenous tissue was present [Table/Fig-1d]. [Table/Fig-2a]

illustrates fibrosis and infiltration by a large number of lymphocytes, suggesting chronic persistent infection. Chronic infection of the ovarian parenchyma appeared to be aetiologically related [Table/Fig-2b]. In addition, a large number of thin-walled microcysts were observed [Table/Fig-2c]. Furthermore, microcysts and capillaries were noted [Table/Fig-2d].



[Table/Fig-1]: a) Shows numerous microcysts, filled with watery serous fluid (H&E, 200x); b) Shows a macrocyst (H&E, 100x); c) Shows numerous microcysts. A few lymphocytes were also observed (H&E, 400x); d) Shows fibrocollagenous tissue infiltrated with a small number of lymphocytes. Microcysts were also seen (H&E, 100x).



[Table/Fig-2]: a) Shows ovarian fibrous parenchyma infiltrated with a large number of lymphocytes (H&E, 100x); b) Photomicrograph shows several large cysts and fibrous tissue (H&E, 100x); c) Shows a large number of thin-walled microcysts (H&E, 100x); d) Shows large number of microcysts and few capillaries (H&E, 400x).

Her menstrual cycles were regular, and her medical history was normal. Moreover, serum levels of Human Chorionic Gonadotropin (HCG), C-Reactive Protein (CRP), and Carcinoembryonic Antigen (CEA) were within the normal range. Follow-up of the patient was uneventful. De-torsion and wedge resection of the diseased ovary appeared to cure the patient with MOE [Table/Fig-3]. The lesion was finally diagnosed as MOE.

DISCUSSION

The MOE was first reported in 1969 by Kalstone CE et al., [1]. The disease may develop in young female during pregnancy [2].

MOE may either develop unilaterally or simultaneously involve both ovaries [3]. It may be associated with mild to moderate ascites. MOE may develop subsequent to strangulation or torsion, resulting in ischaemia of the ovary. The ovary may be enlarged, and its surface may be lobulated. Furthermore, the cut surface may display multiple cysts filled with watery serous fluid. The ovarian stroma may show an accumulation of interstitial fluid [1]. Wedge resection and de-torsion may relieve lower abdominal pain [4].

Surprisingly, multiple adult worms of *Enterobius vermicularis* were found in the appendix of a MOE patient [5]. Partial or complete torsion of the mesovarium may interfere with venous or lymphatic return, leading to the development of MOE. Additionally, MOE may be suspected in a female of reproductive age if she presents with solid enlargement of the ovary. Moreover, a solid ovarian lesion may be regarded as suspicious for malignancy [6].

The MOE is a rare non neoplastic lesion that may occur in young females. Infertility, dysmenorrhoea, precocious puberty, and abdominal distension may be significant presenting clinical features [7]. A more detailed clinicopathological description of Massive Ovarian Edema was provided by Roth LM et al. in 1979, who reported five cases with ultrastructural observations and emphasized its non-neoplastic nature [8]. Oedema may develop suddenly, resulting in acute abdomen, or it may develop intermittently, resulting in a slow progressive clinical disease [5]. Another peculiarity of the current lesion was the presence of necrosis and haemorrhage; however, the latter feature may rarely occur in MOE. A few cases of MOE have been associated with fibromatosis. In another study, Young RH and Scully RE, in 1984, described 14 new cases, with fibromatosis as a predominant finding [9]. Additionally, seven out of 25 cases in a previous study showed evidence of strangulation [9].

Rarely, MOE has been reported in a six-month-old infant as well as in a postmenopausal female [10,11]. The first case of MOE during pregnancy was reported by Gustafson GW et al., in 1954 [12]. Only 12 cases of MOE during pregnancy have been reported. Fibroblastic proliferation with interstitial oedema has been observed previously [13,14]. Clitoromegaly (2 cm) and masculinisation may also occur rarely [15,16]. In addition, Budd–Chiari syndrome has been reported alongside MOE [17]. Torsion of the ovarian pedicle appears to be an important factor in the development of MOE, as de-torsion may reduce the size of an enlarged ovary [18].

Moreover, over 100 cases of MOE have been reported in patients with unilateral or bilateral disease from 1969 to 2011 [13,19]. However, Praveen RS et al., reported 177 cases of MOE, including both primary (n=151) and secondary (n=26) disease. In that report, 76 of the 177 cases were suspected to be due to torsion (43%) [20]. Torsion of the ovary appeared to favour the development of MOE in the first two cases [Table/Fig-3]. Furthermore, de-torsion could reduce the size of the diseased ovary. However, recurrence of oedema did not occur following de-torsion and wedge resection.

Case	Authors and year of study	Clinicopathological features		Treatment
		Role of torsion	Others	
1	Daboubi MK and Khresat B, 2008[16]	Interstitial oedema+Cut surface revealed copious amount of watery serous fluid	Masculinisation+ and size of ovary was 8×6 cm	De-torsion and fixation with uterus
2	Fukuda T et al., 2021[18]	Size of enlarged ovary was reduced following de-torsion	Later, wedge resection was also done	De-torsion treated the patient
3	Ayoola-Adeola M et al., 2021 [15]	Elevated androgen levels	Clitoromegaly+(2 cm)	Not mentioned in the report
4	Raina N et al., 2016 [19]	About 100 cases were reported	Patients developed both unilateral and bilateral lesions	Patient underwent oophorectomy

5	Sehgal A et al., 2022 [17]	Occlusion of hepatic veins may occur (Budd-Chiari syndrome)	Radiological findings were presented	-
6	Present case, 2024	Unilateral, size of ovary was 9×6×4 cm	Cut surface of ovary showed many microcysts	Copious serous fluid oozed from the cut surface

[Table/Fig-3]: Clinicopathological features of five studies, compared with current findings [15-19].
+: Positive

Masculinisation, clitoromegaly, and elevated androgen levels were noted in cases one and three. Moreover, Budd-Chiari syndrome was detected in case five, suggesting ischaemia of the hepatic veins. The current case was very similar to previously reported cases in terms of massive oedema, microcyst formation, and interstitial oedema of the ovary. Moreover, in present case case, de-torsion and/or wedge resection were effective in reducing the size of the diseased ovary, and recurrence was not reported.

CONCLUSION(S)

A young female, aged 23, complained of pain in the lower abdomen. She underwent surgery, and the right ovary was excised. Grossly, the cut surface showed cysts filled with variable amounts of fluid. An excess of water-like serous fluid emerged from the cut surface, and areas of necrosis and haemorrhage were observed. However, a few cases might present with fibrosis. Rarely, oedema may develop suddenly, and the patient might present as a case of acute abdomen. Primary MOE may develop when the ovary is not diseased, while secondary MOE develops due to torsion of a diseased ovary, such as following a cyst, malignant neoplasm, polycystic ovary, or fibromatosis.

REFERENCES

[1] Kalstone CE, Jaffe RB, Abell MR. Massive edema of the ovary simulating fibroma. *Obstet Gynecol.* 1969;34(4):564-71.

[2] Coakley FV, Anwar M, Poder L, Wang ZJ, Yeh BM, Joe BN. Magnetic resonance imaging of massive ovarian edema in pregnancy. *J Comput Assist Tomogr.* 2010;34(6):865-67.

[3] Roberts CL, Weston MJ. Bilateral massive edema: A case report. *Ultrasound Obstet Gynaecol.* 1998;11(1):65-67.

[4] Cheng MH, Tseng JY, Suen JH, Yang CC. Laparoscopic plication of partially twisted ovary with massive ovarian edema. *J Chin Med Assoc.* 2006;69(5):236–239. doi:10.1016/S1726-4901(09)70226-6.

[5] Machairiotis N, Stylianaki A, Kouroutou P, Sarli P, Alexiou NK, Efthymiou E, et al. Massive ovarian oedema: A misleading clinical entity. *Diagn Pathol.* 2016;11:18. Doi: 10.1186/s13000-016-0469-3. PMID: 26843454; PMCID: PMC4739401.

[6] Singh S, Kalra R, Chhabra S, Jain S, Duhan A, Modi S, et al. Massive ovarian edema masquerading as ovarian neoplasm: Report of two cases. *J Gyn Surg.* 2012;28(6):43.

[7] Eden JA. Massive ovarian oedema. *Br J Obst Gynecol.* 1994;101(5):456-58.

[8] Roth LM, Deaton RL, Stenberg WH. Massive ovarian oedema. A clinicopathologic study of five cases including ultrastructural observations and review of the literature. *Am J Surg Pathol.* 1979;3(1):11-21.

[9] Young RH, Scully RE. Fibromatosis and massive oedema of the ovary, possibly related entities: A report of 14 cases of fibromatosis and 11 cases of massive oedema. *Int J Gynecol Pathol.* 1984;3(2):153-78.

[10] Natarajan A, Wales JK, Marven SS, Wright NP. Precocious puberty secondary to massive ovarian edema in a 6-month-old girl. *Eur J Endocrinol.* 2004;150(1):119-23.

[11] Shirk JO, Copas PR, Kattine AA. Massive ovarian edema in a menopausal woman. A case report. *J Reprod Med.* 1996;41(5):359-62.

[12] Gustafson GW, Gardiner SH, Stout FE. Ovarian tumours complicating pregnancy: A review of 45 surgically proved cases. *Am J Obstet Gynecol.* 1954;67(6):1210-23.

[13] Lakshmi KA, Johnson T. Massive edema and fibromatosis of ovary: A rare case report. *Indian J Pathol Oncol.* 2024;11(1):87-89.

[14] Varma A, Chakrabarti PR, Gupta G, Kiyawat P. Massive ovarian edema. A case report presenting as a diagnostic dilemma. *J Family Med Prim Care.* 2016;5(1):172-74.

[15] Ayoola-Adeola M, Sethuram R, Gonullu DC, Awonuga A. Massive ovarian edema masquerading as an androgen-secreting tumor. *F S Rep.* 2021;2(4):468-71.

[16] Daboubi MK, Khresat B. Massive ovarian edema: Literature review and case presentation. *East Mediterr Health J.* 2008;14(4):972-77.

[17] Sehgal A, Prakash A, Kushwaha M, Jain A. Massive ovarian edema mimicking an ovarian neoplasm in a patient with IVC web. *J Radiol Case Rep.* 2022;16(4):17-23.

[18]

Fukuda T, Imai K, Yamauchi M, Kasai M, Ichimura T, Yasui T, et al. Massive ovarian edema with paraovarian cyst torsion treated with laparoscopic surgery: A case report. Med Int (Lond). 2021;1(5):17.

[19]

Raina N, Mardi K, Rana A, Chauhan P. Massive ovarian edema masquerading as fibroma: A rare case report. Clin Cancer Investig J. 2016;5(3):181-83.

[20]

Praveen RS, Pallavi VR, Rajashekar K, Usha A, Umadevi K, Bafna UD. A clinical update on massive ovarian oedema - a pseudotumour? Ecancermedicalsecience. 2013;7:318.

PARTICULARS OF CONTRIBUTORS:

1. Pathologist, Department of Pathology, RML Mehrotra Pathology Pvt. Ltd., Nirala Nagar, Lucknow, Uttar Pradesh, India.
2. Pathologist, Department of Pathology, RML Mehrotra Pathology Pvt. Ltd., Nirala Nagar, Lucknow, Uttar Pradesh, India.
3. Director, RML Mehrotra Pathology Pvt. Ltd, Nirala Nagar, Lucknow, Uttar Pradesh, India.
4. Pathologist, Department of Pathology, RML Mehrotra Pathology Pvt. Ltd., Nirala Nagar, Lucknow, Uttar Pradesh, India.
5. Scientist, Department of Pathology, RML Mehrotra Pathology Pvt. Ltd., Nirala Nagar, Lucknow, Uttar Pradesh, India.

NAME, ADDRESS, E-MAIL ID OF THE CORRESPONDING AUTHOR:

Dr. Ashok Kumar Kapoor
B-171, Nirala Nagar, Lucknow- 22602, Uttar Pradesh, India.
E-mail: drashok Kapoor2016@gmail.com

PLAGIARISM CHECKING METHODS: [\[Jain H et al.\]](#)

- Plagiarism X-checker: Sep 04, 2024
- Manual Googling: Nov 12, 2024
- iThenticate Software: Jan 28, 2025 (1%)

ETYMOLOGY: Author Origin

EMENDATIONS: 7

AUTHOR DECLARATION:

- Financial or Other Competing Interests: None
- Was informed consent obtained from the subjects involved in the study? Yes
- For any images presented appropriate consent has been obtained from the subjects. Yes

Date of Submission: [Sep 03, 2024](#)
Date of Peer Review: [Oct 25, 2024](#)
Date of Acceptance: [Jan 30, 2025](#)
Date of Publishing: [Jul 01, 2025](#)